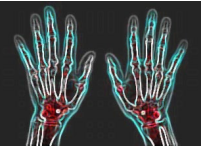

# Managing Patients with Rheumatic Disorders in Primary Care



*Editor's Note: This is a transcript of an online course released in September 2023.*

*To obtain credit for participation, go to <https://www.annenberg.net/courses/landingPage.php?courseID=60410>.*

## MODULE 1: DIAGNOSIS (PART 1)

### ✦ Use of the laboratory in diagnosing rheumatic disorders

A 55-year-old female presents with joint pain and predominantly morning stiffness in her bilateral wrists, second and third metacarpophalangeal (MCP) joints, and knees for 6 months. She has a past medical history of well-controlled hypertension. There is no family history of autoimmune diseases. She is a nonsmoker and occasionally drinks alcohol. She experiences fatigue and morning stiffness in her hands and wrists for over an hour, which improves with movement. Walking up or down stairs is difficult due to knee pain. She denies fever, weight loss, change in bowel habits, or skin rash. Physical examination shows swelling and tenderness in both wrists and knees and slight swelling of the second and third MCP joints bilaterally. Lungs are clear, and there is no rash or adenopathy. Neurological examination is normal. Which of the following test(s) do you recommend for evaluating the etiology of her arthritis?

- A. Anti-CCP and Antinuclear antibodies
- B. Creatinine kinase level and Hepatitis C antibodies
- C. Lyme disease serology
- D. Serum urate levels

**The correct answers are A, B, and D.**

In the context of polyarthritis, with involvement of symmetrical small, medium, and large joints, the anti-cyclic citrullinated peptide (anti-CCP) antibody test is highly specific for rheumatoid arthritis (RA). It can help diagnose RA early in the disease course and is a marker of more aggressive disease, prompting early aggressive treatment.<sup>1</sup>

An antinuclear antibody (ANA) test is a screening tool to detect the presence of autoantibodies that target the cell nuclei. These antibodies are often associated with autoimmune diseases, such as systemic lupus erythematosus (SLE), Sjögren's syndrome, systemic sclerosis, and rheumatoid arthritis.<sup>2</sup> This patient presents with joint pain, stiffness, and objective swelling, which could indicate autoimmune arthritis like SLE or

rheumatoid arthritis (RA). A positive ANA test, however, is not a definitive diagnostic test for autoimmune disease and should prompt additional antibody testing (eg, anti-double-stranded DNA) in this setting.

Hepatitis C infection is associated with various extrahepatic manifestations, including inflammatory polyarthritis involving small and large joints.<sup>3</sup> Therefore, screening for hepatitis C antibodies is crucial to determine if this infection could be causing the patient's joint issues, which can mimic rheumatoid arthritis. Importantly, patients with hepatitis C infection may have high levels of rheumatoid factor, although they are almost invariably negative if tested for anti-CCP.

Gout commonly manifests with sudden and severe joint pain, frequently affecting the big toe or foot.<sup>4</sup> While acute polyarthritis due to gout can occur in some patients, it is not the typical presentation, and chronic arthritis would not be expected, especially during the initial onset. Therefore, an elevated serum urate level alone would not be sufficient for a definitive diagnosis of gout.

Elevated CK levels are expected in patients with muscle inflammation or muscle injury. Patients with inflammatory myopathies may have accompanying polyarthritis. Since the patient's primary complaint is joint pain and stiffness, and the neurologic examination is normal without specific symptoms or examination findings of muscle weakness, interstitial lung disease, or a dermatomyositis rash, measuring the CK level is not likely to be helpful.<sup>5</sup>

Although Lyme disease can be associated with inflammatory arthritis, the pattern of arthritis is generally mono- or oligoarticular, involving large joints. It is not a small joint symmetric polyarthritis. It is typically associated with a history of tick exposure and a characteristic skin rash (erythema migrans).<sup>6</sup> However, the rash may occur months prior to arthritis or may not have been noticed. Nonetheless, it would be helpful to note if the patient had spent time during the spring/fall in areas where Lyme disease is endemic.

# Managing Patients with Rheumatic Disorders in Primary Care



## References:

1. Avouac J, Gossec L, Dougados M. Diagnostic and predictive value of anti-cyclic citrullinated protein antibodies in rheumatoid arthritis: a systematic literature review. *Ann Rheum Dis*. 2006;65(7):845-851. doi:10.1136/ard.2006.051391
2. Kumar Y, Bhatia A, Minz RW. Antinuclear antibodies and their detection methods in diagnosis of connective tissue diseases: a journey revisited. *Diagn Pathol*. 2009;4:1. doi:10.1186/1746-1596-4-1
3. Riccio A, Tarantino G. Hepatitis C virus-related arthritis and rheumatoid arthritis: could they be different aspects of the same disease? *Int J Immunopathol Pharmacol*. 2012;25(1):293-296. doi:10.1177/039463201202500134
4. Pillinger MH and Mandell BF. Therapeutic approaches in the treatment of gout. *Semin Arthritis Rheum*. 50: S24-30, 2020. doi:10.1016/j.semarthrit.2020.04.010.
5. Mammen AL. Autoimmune Myopathies. *Continuum (Minneapolis, Minn)*. 2016;22(6, Muscle and Neuromuscular Junction Disorders):1852-1870. doi:10.1212/01.CON.0000511070.50715.ab
6. Lochhead RB, Strle K, Arvikar SL, Weis JJ, Steere AC. Lyme arthritis: linking infection, inflammation and autoimmunity. *Nat Rev Rheumatol*. 2021;17(8):449-461. doi:10.1038/s41584-021-00648-5

## ✦ Distinguishing etiologies of inflammatory arthropathies

A 34-year-old male presents with joint pain and swelling affecting 2 distal interphalangeal joints (fourth on right and second on left), right knee, and left ankle. He has morning stiffness that lasts at least 30 minutes in the knee. Physical examination reveals tenderness and swelling of the affected joints, and the second digit of his left hand appears swollen from the metacarpophalangeal to the fingernail. The patient denies other symptoms, including fever, weight loss, fatigue, oral ulcers, eye problems, abdominal pain, or diarrhea. Laboratory tests show an erythrocyte sedimentation rate of 18 mm/hr (normal: 0 – 15 mm/hr) and a C-reactive protein level of 10 mg/L (normal: < 10 mg/L).

Which component(s) of a directed physical examination will most likely contribute to the diagnosis?

- A. Examination of lacrimal glands and slit-lamp eye exam
- B. Nail examination and palpation of Achilles insertion on the calcaneus
- C. Perirectal examination and SI joint exam
- D. SI joint exam and measuring low spine mobility (Schober test)

### The correct answers are B, C, and D.

The patient presents with dactylitis (swollen digit), highly characteristic of psoriatic arthritis, spondylitis, and occasionally inflammatory bowel disease. Psoriasis can present with nail changes, including pitting, discoloration, and onycholysis.<sup>1</sup> A thorough examination of the nails and skin can

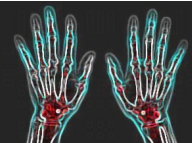
provide valuable clues to diagnose psoriasis. Areas that may be involved with psoriasis, yet not noted by the patient, include behind the ears, scalp, gluteal crease, and umbilicus. Marked inflammatory involvement of the distal interphalangeal joints also suggests psoriatic arthritis.

Other forms of inflammatory arthritis, particularly ankylosing spondylitis, which primarily affects the spine and sacroiliac (SI) joints, can be associated with dactylitis. The Schober test, which measures the distance between 2 points on the patient's lower back during flexion, is a simple clinical measure to assess the mobility of the lumbar spine.<sup>2</sup> Restricted spine mobility and SI joint tenderness can support the diagnosis of ankylosing spondylitis (or spondylitis associated with psoriasis or inflammatory bowel disease).

Dactylitis or other arthritis in some settings can be associated with enthesitis (inflammation at the site of attachment of tendons to bone), particularly common in psoriatic arthritis and spondylitis.<sup>3</sup> A common site for enthesitis is the Achilles tendon insertion at the back of the heel. Detecting tenderness and swelling in this area during palpation can provide additional evidence supporting the diagnosis of spondyloarthritis, reactive arthritis, or psoriatic arthritis.

A perirectal examination is relevant when evaluating inflammatory conditions involving dactylitis or the SI joints and spine. A perirectal (gluteal crease) examination can assess for the presence of psoriasis.<sup>4</sup>

# Managing Patients with Rheumatic Disorders in Primary Care



Examining the lacrimal gland is relevant when evaluating conditions that may affect tear production and cause dry eyes, such as Sjögren's syndrome or especially sarcoidosis. However, the patient in the case presentation does not report any eye problems or symptoms associated with Sjögren's syndrome or sarcoidosis. Both entities can be related to arthritis, but not in this pattern. Sarcoidosis can very rarely cause dactylitis.

A slit lamp eye exam is useful to assess the eyes for uveitis, which can occur in ankylosing spondylitis, psoriatic arthritis, sarcoidosis, and some other inflammatory conditions.<sup>5</sup> However, there are no indications in the case presentation that the patient has any symptoms of uveitis, which are usually present when associated with inflammatory arthritis, other than in children with the oligoarticular form of juvenile idiopathic arthritis. Thus, this would not likely be helpful.

## References:

1. Coates LC, Helliwell PS. Psoriatic arthritis: state of the art review. *Clin Med (Lond)*. 2017;17(1):65-70. doi:10.7861/clinmedicine.17-1-65
2. Yen YR, Luo JF, Liu ML, Lu FJ, Wang SR. The anthropometric measurement of Schober's test in normal Taiwanese population. *Biomed Res Int*. 2015;2015:256365. doi:10.1155/2015/256365
3. Wu X, Liu D, Li Y, et al. A clinical practice guideline for the screening and assessment of enthesitis in patients with spondyloarthritis. *Front Immunol*. 2022;13:978504. Published 2022 Sep 12. doi:10.3389/fimmu.2022.978504
4. Dydyk AM, Forro SD, Hanna A. Sacroiliac Joint Injury. In: *StatPearls*. Treasure Island (FL): StatPearls Publishing; January 15, 2023.
5. Rosenbaum JT, Bodaghi B, Couto C, et al. New observations and emerging ideas in diagnosis and management of non-infectious uveitis: A review. *Semin Arthritis Rheum*. 2019;49(3):438-445. doi:10.1016/j.semarthrit.2019.06.004

## ❖ Young boy with knee pain – diagnostic evaluation

A 7-year-old boy presents with joint pain and swelling in both knees. His symptoms have been present for the past 3 months and are associated with morning stiffness when dressing for school. He denies pain, but his teacher notes that he is running with a limp at recess. The boy's parents report no history of rash, fevers, abdominal pain, or change in appetite or bowel habits. Physical examination reveals moderate bilateral knee effusions without tenderness. The rest of his exam is unremarkable. Laboratory investigation reveals a hemoglobin of 10.5 gm/dL (normal: 12.3 – 15.3 gm/dL) and erythrocyte sedimentation of 23 mm/hr (normal: <10 mm/hr).

Which tests are likely to be most helpful to his diagnosis and management?

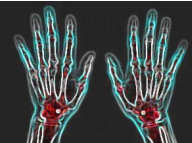
- A. Anti-CCP antibody and bone marrow examination
- B. Anti-parvo virus antibody and Stool occult blood test
- C. Lyme antibody studies and slit-lamp examination
- D. Slit-lamp eye examination and Stool occult blood test

## The correct answers are C and D.

The patient's presentation raises suspicion for juvenile idiopathic arthritis (JIA). Some subtypes of JIA, such as oligoarticular JIA, may be associated with uveitis.<sup>1</sup> Uveitis associated with JIA can be asymptomatic in its early stages or may cause eye redness, light sensitivity, and blurred vision.<sup>2</sup> Regular eye examinations, including a slit lamp examination, are crucial in identifying and managing uveitis promptly to prevent potential complications including vision loss. Depending upon its location in the uveal tract of the eye, the presence of otherwise unexplained uveitis can also help define the diagnosis.

Joint pain and swelling, especially in large joints like the knees, can be a manifestation of Lyme disease, particularly in children.<sup>3</sup> Since the patient's symptoms have been present for 3 months, if there is a possibility of prior exposure to Lyme disease-carrying ticks, Lyme antibody tests, such as ELISA, are commonly used as initial screening tests. A Western blot test is performed to confirm likely infection if the ELISA is positive or equivocal. Early diagnosis and treatment of Lyme disease are essential to prevent complications, including chronic or recurrent Lyme arthritis.

# Managing Patients with Rheumatic Disorders in Primary Care



The patient's anemia and elevated erythrocyte sedimentation rate warrant further investigation. A positive stool test for blood can suggest occult gastrointestinal bleeding associated with inflammatory bowel disease (IBD).<sup>4</sup> Arthritis associated with IBD can manifest before fulminant GI symptoms.

Anti-CCP antibody testing is used to help diagnose rheumatoid arthritis (RA) in adults.<sup>5</sup> JIA is distinct from adult-onset RA, and anti-CCP antibody testing is not routinely recommended for diagnosing JIA in young children with this distribution of joint symptoms.

While Parvovirus B19 infection can lead to joint pain and swelling, typically in adults, it is unlikely to

explain the prolonged joint symptoms experienced by this boy for three months. Positive serologies for anti-parvovirus antibodies are common due to the high prevalence of often asymptomatic infections. Consequently, anti-parvovirus antibody testing is not expected to provide helpful insights in this case.

A bone marrow examination is an invasive procedure not indicated in this case. The patient's presentation, with oligoarticular joint pain, swelling, anemia, and an elevated erythrocyte sedimentation rate without fevers or other cytopenias, suggests inflammation. Still, it does not indicate a need for a bone marrow examination. Systemic onset JIA, with fevers and arthritis, can rarely be the presentation of leukemia.

## References:

1. Barut K, Adrovic A, Şahin S, Kasapçopur Ö. Juvenile idiopathic arthritis. *Balkan Med J.* 2017;34(2):90-101. doi:10.4274/balkanmedj.2017.0111
2. Weiss JE, Ilowite NT. Juvenile idiopathic arthritis. *Pediatr Clin North Am.* 2005;52(2):413-vi. doi:10.1016/j.pcl.2005.01.007
3. Gerber MA, Zemel LS, Shapiro ED. Lyme arthritis in children: clinical epidemiology and long-term outcomes. *Pediatrics.* 1998;102(4 Pt 1):905-908. doi:10.1542/peds.102.4.905
4. De Filippo C, Di Paola M, Giani T, Tirelli F, Cimaz R. Gut microbiota in children and altered profiles in juvenile idiopathic arthritis. *J Autoimmun.* 2019;98:1-12. doi:10.1016/j.jaut.2019.01.001
5. Wu CY, Yang HY, Luo SF, Lai JH. From rheumatoid factor to anti-citrullinated protein antibodies and anti-carbamylated protein antibodies for diagnosis and prognosis prediction in patients with rheumatoid arthritis. *Int J Mol Sci.* 2021;22(2):686. Published 2021 Jan 12. doi:10.3390/ijms22020686

## ✦ Evaluating back pain

A 45-year-old female complains of back pain for the past 10 months. She describes the pain as worse in the mornings and improving throughout the day with activity. There is no history of trauma, and the symptoms have slowly worsened. The pain is associated with morning back stiffness lasting more than 45 minutes, making it hard to dress. She notes the recent onset of bilateral posterior heel pain. She has no significant past medical history, is a nonsmoker, and does not consume alcohol excessively. She works as a computer programmer and leads a sedentary lifestyle. She denies fever, weight loss, eye problems, bowel disturbances, or skin lesions. Physical examination reveals decreased spine flexion with normal hip rotation without pain. There is tenderness laterally over both hip trochanters and Achilles insertions. Laboratory tests include a normal CBC, C-reactive protein, and erythrocyte sedimentation rate. Hip and lumbar X-

rays are normal. She describes poor sleep over the past year, with awakenings early mornings with generalized pain, mainly in the low and mid-back. Lumbar spine (with special views of the SI joints) X-rays are normal.

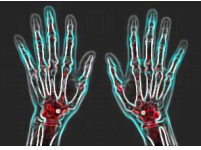
What studies/interventions will likely help evaluate and design a management plan?

- A. CT pelvis with IV and oral contrast and Ultrasound of the abdominal aorta
- B. HLA B27 and MRI of the lumbar spine without contrast
- C. Rheumatoid factor and anti-CCP antibody levels
- D. Sleep study, physical therapy, and trial of bedtime trazodone

**The correct answer is B.**

The patient's clinical presentation and history suggest the possibility of an inflammatory condition affecting the spine. MRI is more sensitive than

# Managing Patients with Rheumatic Disorders in Primary Care



standard radiographs in detecting early signs of inflammation in the spine, making it an essential imaging modality for evaluating inflammatory back pain and conditions like ankylosing spondylitis and other spondyloarthropathies when a strongly suggestive history is described, and radiographs are unrevealing.<sup>1</sup>

While the presence of HLA B27 is not specific to ankylosing spondylitis, its detection in the appropriate clinical setting can provide additional supportive evidence for diagnosing spondylitis. Up to 95% of White individuals with ankylosing spondylitis are HLA B27 positive.<sup>2</sup> However, it is essential to note that the absence of HLA B27 does not rule out ankylosing spondylitis, as the condition can occur in individuals who are HLA B27 negative. Patients may have the gene without any associated clinical disease.

A CT scan of the pelvis with IV and oral contrast is not indicated. While CT scans can help evaluate bony structures, they are not the primary imaging modality for assessing inflammation in the spine. The described symptoms and examination do not suggest a pelvic or intra-abdominal process.

Rheumatoid factor and anti-cyclic citrullinated peptide (CCP) antibodies are tests used in diagnosing rheumatoid arthritis (RA), which differs from ankylosing spondylitis. The patient's clinical presentation, including morning stiffness of the low back lasting more than 45 minutes and tenderness over the trochanters and Achilles insertions, suggests an inflammatory condition affecting the spine rather than RA (which does not usually affect the low back).

While a sleep study and physical therapy may be beneficial for addressing sleep disturbances and general back pain management, they will not directly address the specific underlying cause of her symptoms, which appear to be related to an inflammatory condition affecting the spine. Trazodone is a valuable medication in some patients with primary sleep disorders but does not help control inflammatory back pain.

The patient's presentation and symptoms do not suggest any abdominal aortic pathology. The evaluation should focus on the spine and possible inflammatory conditions that can cause back pain, morning stiffness, and heel pain. Ultrasound of the abdominal aorta is not relevant to the current clinical scenario.

## References:

1. Ostergaard M, Lambert RG. Imaging in ankylosing spondylitis. *Ther Adv Musculoskelet Dis.* 2012;4(4):301-311. doi:10.1177/1759720X11436240
2. Zhu W, He X, Cheng K, et al. Ankylosing spondylitis: etiology, pathogenesis, and treatments. *Bone Res.* 2019;7:22. Published 2019 Aug 5. doi:10.1038/s41413-019-0057-8



# Managing Patients with Rheumatic Disorders in Primary Care



## MODULE 2: DIAGNOSIS (PART 2)

### ✦ Laboratory assessments for inflammatory arthritis

A 46-year-old female presents with a 2-month history of worsening pain in her bilateral feet and hands. She has noticed swelling in her feet and hands, particularly in the mornings. She has experienced significant fatigue over the same period. The symptoms have progressively worsened, impacting her daily activities. Her medical history includes a recent cough and shortness of breath with exertion. On physical examination, she is afebrile with normal blood pressure, pulse, and respiratory rate. No joint swelling is noted. She walks with a slight limp with reduced right ankle flexion, and there is isolated weakness of ankle flexion on examination and a reduced ankle stretch reflex. Testing of upper extremity abduction and hip extension/flexion strength is normal. There is no adenopathy. Chest examination reveals bibasilar crackles and no murmur. Laboratory tests reveal a positive rheumatoid factor, Hgb of 9.0 gm/dL (normal: 12.3 gm/dL - 15.3 gm/d), and platelets of 452 x 10<sup>9</sup>/L (normal: 150 - 350 x 10<sup>9</sup>/L). The ALT and AST are normal. A chest radiograph is normal.

Which tests would you order to help establish this patient's diagnosis?

- A. CCP and Creatinine kinase levels
- B. CT chest and EMG
- C. MRI spine and Urinalysis
- D. Urinalysis and EMG

**The correct answers are B and D.**

The patient's presentation of bilateral foot and hand pain with subjective swelling, generalized fatigue, dyspnea with crackles on examination, and foot drop raises concern for a systemic process such as vasculitis. Vasculitis, such as microscopic polyangiitis, can affect the lungs and peripheral nerves and cause systemic symptoms. The kidneys can be seriously involved without causing any specific initial symptoms.<sup>1,2</sup> To evaluate and "stage"

organ involvement of a multisystem inflammatory disorder, a urinalysis with prompt microscopic evaluation of fresh urine sediment is mandatory to look for evidence of glomerulonephritis.

In addition, the patient's slight limp due to weakness in the right ankle flexion indicates likely nerve involvement. An EMG can assess nerve conduction and muscle function, contributing to the evaluation of her symptoms, especially with the systemic nature of her complaints.

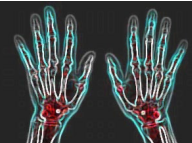
Given the scattered bibasilar crackles mentioned in the physical examination, a chest CT scan is crucial in evaluating the lungs for interstitial lung disease or alveolar hemorrhage, even with a normal chest radiograph. The marked anemia raises concern in this setting for alveolar hemorrhage, even in the absence of hemoptysis.

A spine MRI is not the first-line diagnostic test in this context. There are no specific indications in the given information to suggest that the spine is the primary focus of the patient's symptoms. The clinical presentation and systemic signs point toward a broader systemic process rather than isolated spinal involvement causing the foot drop.

While the patient experiences muscle pain and a sense of weakness and fatigue, nothing specific on the examination suggests a myopathy, which would not cause a foot drop. Although muscle can be involved in systemic vasculitis, creatinine kinase (CK) levels would not likely provide direct information about the patient's underlying systemic condition.

Similarly, CCP testing, helpful in diagnosing rheumatoid arthritis, is not relevant to the current suspected diagnosis, despite positive rheumatoid factor (which is not uncommon in several forms of primary or secondary vasculitis). The goal is to document and stage a potential vasculitis or other systemic condition affecting multiple organs. Hepatitis C and B infections should be excluded, as both can cause systemic vasculitis, although interstitial disease is not as frequent as neurologic and renal involvement.

# Managing Patients with Rheumatic Disorders in Primary Care



## References:

1. Yaseen, K and Mandell BF. ANCA Associated Vasculitis (AAV): A Review for Internists. *Postgrad Med.* 1-11, 2022. doi:10.1080/00325481.2022.2102368
2. Stanton M, Tiwari V. Polyarteritis Nodosa. In: *StatPearls*. Treasure Island (FL): StatPearls Publishing; February 22, 2023.

## ✦ Laboratory assessments for possible SLE

A 32-year-old female teacher presents with a 3-month history of progressive fatigue, joint pain, and a facial rash. She describes tiredness in her extremities while walking upstairs at school, requiring her to use the elevator, intermittent fevers up to 100.5 degrees Fahrenheit, and mild bitemporal hair loss. She has no significant medical or family history of autoimmune diseases and leads an active lifestyle with moderate social alcohol consumption. During the physical examination, tenderness and mild swelling are observed in multiple joints (wrists, metacarpophalangeal joints, proximal interphalangeal joints). Additionally, she has nontender enlarged axillary and epitrochlear lymph nodes. On her face and chest, scattered erythematous annular plaques are present, along with periungual erythema on all her fingers. Laboratory investigations reveal a normal complete blood count and creatinine but elevated AST and ALT levels (3 times the normal range). Antinuclear antibodies are positive with a 1:640 homogenous pattern, while hepatitis B and C serologies, RPR, and EBV studies are negative.

Which of the following studies should be done rapidly to help direct initial management?

- Anti-DNA antibodies
- Creatine kinase level
- CT chest and abdomen
- Liver biopsy
- Urinalysis

**The correct answers are A, B, and E.**

The patient's symptoms strongly suggest systemic lupus erythematosus (SLE). Identifying kidney involvement is crucial since lupus nephritis can cause substantial kidney damage if not detected and managed early.<sup>1</sup> A urinalysis can detect

glomerulonephritis with microscopic hematuria and casts on examination of fresh urine sediment.

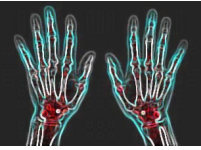
The patient's symptoms of fatigue, with difficulty walking upstairs, suggest muscle weakness, raising suspicion for myositis, which can be associated with SLE.<sup>2</sup> Measuring creatine kinase levels can help confirm or rule out myositis as the cause of muscle symptoms. Myocytes contain AST and ALT. Thus, myositis can be associated with significant elevations of these amino transaminases.<sup>3</sup>

While antinuclear antibodies (ANA) are already positive, they lack specificity for lupus and can be present in other autoimmune conditions. Testing for anti-DNA and anti-Smith antibodies, which are more specific for SLE, can enhance diagnostic accuracy.<sup>4</sup> The detection of anti-DNA antibodies helps confirm the lupus diagnosis and distinguishes it from other conditions with positive ANA. The anti-DNA antibodies, unlike the ANA, may fluctuate with disease activity. Autoimmune myositis can also be associated with a positive ANA.

At this stage, a liver biopsy is not the most immediate or suitable test, even considering the elevation of "liver" enzymes (AST and ALT), which, as noted above, are NOT specific to the liver. The patient's clinical presentation suggests a higher likelihood of lupus with muscle involvement than primary autoimmune liver disease. The initial priority should be ruling out kidney involvement and myositis and confirming the diagnosis of lupus.

A chest and abdomen CT scan is not the most urgent or specific test for addressing the current symptoms and concerns. The focus should be on targeted tests, such as urinalysis, CK level measurement, and specific antibody testing, to better evaluate and diagnose lupus or myositis with potential complications.

# Managing Patients with Rheumatic Disorders in Primary Care



## References:

1. Almaani S, Meara A, Rovin BH. Update on lupus nephritis. *Clin J Am Soc Nephrol.* 2017;12(5):825-835. doi:10.2215/CJN.05780616
2. Liang Y, Leng RX, Pan HF, Ye DQ. Associated variables of myositis in systemic lupus erythematosus: A cross-sectional study. *Med Sci Monit.* 2017;23:2543-2549. Published 2017 May 26. doi:10.12659/msm.902016
3. Benveniste, O, Musset, L. (2020). Making the Diagnosis of Myositis: Laboratory Testing in Myositis. In: Aggarwal, R, Oddis, C. (eds) *Managing Myositis.* Springer, Cham. [https://doi.org/10.1007/978-3-030-15820-0\\_17](https://doi.org/10.1007/978-3-030-15820-0_17)
4. Infantino M, Nagy E, Bizzaro N, Fischer K, Bossuyt X, Damoiseaux J. Anti-dsDNA antibodies in the classification criteria of systemic lupus erythematosus. *J Transl Autoimmun.* 2021;5:100139. Published 2021 Dec 28. doi:10.1016/j.jtauto.2021.100139

## ✦ Recognizing extra-articular manifestations

A 28-year-old woman with seropositive rheumatoid arthritis (CCP and RF antibodies) has well-managed joint symptoms with a weekly dose of 15 mg methotrexate, 1 mg daily folic acid, and occasional naproxen use. However, she now experiences dry and gritty eyes, occasional sharp eye pains in the morning, and persistent dry mouth throughout the day. Dental examination shows no caries. Physical examination reveals mild synovial proliferation in the right hand's second and third metacarpophalangeal joints and slight demineralization in bilateral carpal bones on X-rays. There is no parotid gland enlargement. Eye examination shows slight redness without nodularity, and salivary pooling is reduced with noticeable lipstick on the upper incisors.

Which of the following will likely impact her disease course and management?

- A. Addition of hydroxychloroquine to her regimen
- B. Checking the SSA and SSB antibodies
- C. Increase the frequency of dental examinations with the use of fluoride
- D. Lubricating eye drops during the day and ointment at bedtime
- E. Ophthalmology examinations with consideration for ductal plugging and topical calcineurin antagonist therapy

**The correct answers are C, D, and E.**

The patient's symptoms of dry eyes and mouth throughout the day and noticeable lipstick on the upper incisors indicate likely autoimmune exocrine gland dysfunction or Sjögren's syndrome. Sjögren's syndrome frequently coexists with rheumatoid arthritis, SLE, scleroderma, and other systemic autoimmune disorders (secondary Sjögren's).<sup>1</sup>

Decreased quality and quantity of saliva can increase the risk of dental caries, making regular dental examinations crucial to monitor for oral complications.<sup>2</sup> Additionally, fluoride use may help prevent tooth decay and should be considered in the management plan.<sup>3</sup> Medications should be reviewed to see if any medications that cause mouth dryness can be eliminated.

The patient's dry and gritty eyes with intermittent sharp eye pains suggest dry eye syndrome, which is part of Sjögren's syndrome.<sup>4</sup> To alleviate discomfort and manage dry eye symptoms effectively, lubricating eye drops during the day and eye ointment at bedtime can be helpful.<sup>5</sup>

Ophthalmology examinations are essential to assess the severity of dry eye syndrome and identify potential complications related to Sjögren's syndrome. Artificial lubricants, plugging of the tear ducts, and prescribed topical calcineurin antagonist therapy can be considered for managing ocular surface dryness in Sjögren's-related dry eye syndrome.<sup>6</sup> An ophthalmologist's evaluation will help tailor an appropriate treatment plan for her eye-related symptoms.

While a positive SSA or SSB is common in patients with Sjögren's syndrome, and these are frequently checked to support the diagnosis, demonstrating the presence of these antibodies will not immediately impact her management. Their presence becomes relevant if she becomes pregnant due to the increased risk of congenital complete heart block in the presence of these antibodies in the mother.<sup>7</sup>

Although hydroxychloroquine may be used in managing rheumatoid arthritis, there is no specific indication for adding it to the patient's current



# Managing Patients with Rheumatic Disorders in Primary Care



treatment regimen based on the provided information. Her joint symptoms are well managed with the current treatment, and the focus should be on addressing her new symptoms of dry eyes and

mouth, which suggest Sjögren's syndrome. No robust data suggest that hydroxychloroquine is beneficial in treating the symptoms of Sjögren's syndrome.

## References:

1. Harrold LR, Shan Y, Rebello S, et al. Prevalence of Sjögren's syndrome associated with rheumatoid arthritis in the USA: an observational study from the Corrona registry. *Clin Rheumatol.* 2020;39(6):1899-1905. doi:10.1007/s10067-020-05004-8
2. Su N, Marek CL, Ching V, Grushka M. Caries prevention for patients with dry mouth. *J Can Dent Assoc.* 2011;77:b85.
3. Medjedovic E, Medjedovic S, Deljo D, Sukalo A. IMPACT OF FLUORIDE ON DENTAL HEALTH QUALITY. *Mater Sociomed.* 2015;27(6):395-398. doi:10.5455/msm.2015.27.395-398
4. Akpek EK, Bunya VY, Saldanha IJ. Sjögren's syndrome: More than just dry eye. *Cornea.* 2019;38(5):658-661. doi:10.1097/ICO.0000000000001865
5. Michaelov E, McKenna C, Ibrahim P, Nayeni M, Dang A, Mather R. Sjögren's syndrome associated dry eye: Impact on daily living and adherence to therapy. *J Clin Med.* 2022;11(10):2809. Published 2022 May 16. doi:10.3390/jcm11102809
6. Kate A, Shanbhag SS, Donthineni PR, Amescua G, Quinones VLP, Basu S. Role of topical and systemic immunosuppression in aqueous-deficient dry eye disease. *Indian J Ophthalmol.* 2023;71(4):1176-1189. doi:10.4103/IJO.IJO\_2818\_22
7. De Carolis S, Garufi C, Garufi E, et al. Autoimmune congenital heart block: A review of biomarkers and management of pregnancy. *Front Pediatr.* 2020;8:607515. Published 2020 Dec 22. doi:10.3389/fped.2020.607515

## ❖ Diagnosis of Systemic Autoimmune Disease

A 31-year-old female presents with marked fatigue that has increased over the past 10 years. She experiences intense exhaustion after more than usual activity, sometimes requiring daily bed rest to recover. She also reports diffuse muscle pain in her arms and legs during use, without joint swelling. She does not have Raynaud's phenomenon. Her CBC, TSH, creatine kinase, and CMP results are normal. She occasionally experiences tingling and burning sensations in her extremities. She has no swollen joints or rashes and has normal proximal muscle strength and distal monofilament sensation. Which of the following tests would be appropriate for this patient to direct therapy?

- A. ANA (Antinuclear Antibodies)
- B. Anti-thyroid peroxidase antibodies
- C. RF (Rheumatoid Factor)
- D. SSA antibodies
- E. None of these

## The correct answer is E.

The patient's clinical presentation with marked fatigue, exhaustion after activity, pain in arms and legs during use, and intermittent tingling and burning sensations in extremities with normal

strength, normal sensation, and normal joint examination does not suggest a high likelihood of systemic lupus erythematosus (SLE) or other systemic autoimmune rheumatic diseases.

Studies have shown that ordering ANA testing in patients with only fatigue and constitutional symptoms has a very low positive predictive value (PPV) for diagnosing SLE. For example, one observational study found that among 1,010 patients tested for ANA, only 2% were diagnosed with SLE, and the PPV for SLE in patients with only fatigue and constitutional symptoms was approximately 0%.<sup>1</sup> Another retrospective review of 232 patients referred to rheumatology to evaluate positive ANA found a PPV of 2.1% for SLE and 9.1% for any ANA-related disease. No ANA-related disease was diagnosed in patients with ANA titers less than 1:160.<sup>2</sup>

# Managing Patients with Rheumatic Disorders in Primary Care



Given the normal TSH, ordering specific autoimmune antibodies like anti-thyroid peroxidase is also not indicated in this case. Hashimoto's thyroiditis (positive anti-thyroid antibodies) with a normal TSH would not be expected to cause these

symptoms. The presence of a positive SSA antibody, like with ANA, would not define the presence of a systemic autoimmune disease, including Sjogren's syndrome, and even if positive, would not prompt the use of systemic therapy.

## References:

1. Slater CA, Davis RB, Shmerling RH. Antinuclear antibody testing. A study of clinical utility. *Arch Intern Med.* 1996;156(13):1421-1425.
2. Abeles AM, Abeles M. The clinical utility of a positive antinuclear antibody test result. *Am J Med.* 2013;126(4):342-348. doi:10.1016/j.amjmed.2012.09.014

## MODULE 3: TARGETS AND TREATMENTS

### ✦ Targeted treatments for PsA

A 42-year-old male presents to your clinic with a 5-year history of psoriatic arthritis. Despite previous treatment with NSAIDs, methotrexate, and sulfasalazine, he has active joint inflammation with moderate pain and swelling. He also reports morning stiffness lasting for 45-60 minutes.

Before initiating which of the following medications, should the administration of a herpes zoster vaccine be considered?

- A. Anti-CD20
- B. IL-6 inhibitors
- C. IL-17 inhibitors
- D. JAK inhibitors
- E. TNF inhibitors

## References:

1. Sunzini F, McInnes I, Siebert S. JAK inhibitors and infections risk: focus on herpes zoster. *Ther Adv Musculoskelet Dis.* 2020;12:1759720X20936059. Published 2020 Jun 29. doi:10.1177/1759720X20936059

### ✦ Targeted treatments for axial SpA

A 28-year-old male presents to the rheumatology clinic with back pain and stiffness that has persisted for the past 3 years. He says the pain is primarily in the lower back and buttocks, worsens when waking up in the morning, and improves with activity. The patient was previously treated with NSAIDs and tumor necrosis factor inhibitors. Physical examination reveals limited lumbar spine flexion (Schober test measures 2 cm, with the normal range being >5 cm) and tenderness over the sacroiliac joints with normal hip motion. Laboratory tests show an elevated C-reactive protein, negative rheumatoid factor, and positive HLA-B27 testing. Imaging studies reveal bilateral sacroiliitis.

The correct answer is D.

Patients with psoriatic arthritis often require immunosuppressive medications to control their disease. However, these medications can increase the risk of developing certain infections, including herpes zoster (shingles), which is caused by the reactivation of the varicella-zoster virus (VZV). To reduce the risk of herpes zoster, it is essential to consider vaccination before initiating certain immunosuppressive therapies.

While all immunosuppressants may increase the risk for herpes zoster, the JAK inhibitors (and moderate to high dose corticosteroids) seem to pose the greatest risk,<sup>1</sup> and vaccination with the newer nonlive vaccine should be considered before initiation of therapy, even in patients who are younger than 50 (but >18). Additionally, of the above choices, A and B are not generally used to treat psoriatic arthritis.

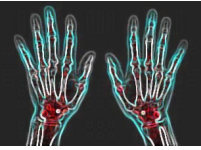
Which of the following treatments would be appropriate for managing this patient with nonradiographic axial spondylarthritis?

- A. Certolizumab
- B. Ixekizumab
- C. Methotrexate
- D. Secukinumab
- E. Upadacitinib

The correct answers are A, B, D, and E.

Ixekizumab is a monoclonal antibody that targets and inhibits interleukin-17A (IL-17A), which is involved in the inflammatory process of various autoimmune conditions, including spondyloarthritis. The FDA has approved it for

# Managing Patients with Rheumatic Disorders in Primary Care



treating active radiographic and nonradiographic axial spondyloarthritis (nr-axSpA) in adults with inadequate response or intolerance to NSAIDs.<sup>1</sup> One study analyzed data from 3 trials of ixekizumab in patients with radiographic and nr-axSpA, revealing that female patients initially had a higher disease burden, with males exhibiting more robust treatment responses up to 16 weeks, while females displayed less pronounced responses initially but showed greater improvement from weeks 16 to 52.<sup>2</sup> Given the patient's symptoms and diagnosis of spondyloarthropathy, ixekizumab could be an appropriate treatment option for him.

Secukinumab is another monoclonal antibody that targets and neutralizes IL-17A. It has also been FDA-approved for treating active radiographic or nr-axSpA in adults with inadequate response or intolerance to first-line therapy.<sup>3</sup> One study analyzed radiographic progression and inflammation over 2 years in patients with nr-axSpA treated with secukinumab, finding minimal changes in structural damage, sustained reduction in sacroiliac joint inflammation, and low spinal inflammation on MRI in both secukinumab and placebo-secukinumab groups.<sup>4</sup> Another study demonstrated that secukinumab effectively improved disease activity in axSpA patients, with higher response rates in treatment-naive and second-line patients, and exhibited favorable persistence rates for up to 24 months of treatment.<sup>5</sup> Like ixekizumab, secukinumab can be considered as a treatment option for this patient.

Upadacitinib is a Janus kinase inhibitor that inhibits specific enzymes involved in the inflammatory

process. It has been approved for treating active radiographic or nr-axSpA in adults with active axial spondyloarthritis with objective signs of inflammation who have had an inadequate response or intolerance to TNF blocker therapy.<sup>6</sup> In the SELECT-AXIS 2 trial, upadacitinib demonstrated significant efficacy in improving signs and symptoms of nr-axSpA compared to placebo at week 14, with a favorable safety profile.<sup>7</sup> Therefore, upadacitinib is a suitable treatment option for this patient's condition.

Certolizumab is a TNF inhibitor that targets TNF-alpha, a proinflammatory cytokine involved in spondyloarthritis. It has also been approved for treating adults with active radiographic or nr-axSpA with objective signs of inflammation.<sup>8</sup> The 52-week results from the C-axSpA trial demonstrated that certolizumab is a safe and effective long-term treatment option for active nr-axSpA, with sustained clinical improvements and reduced inflammation observed for up to 3 years.<sup>9</sup> While the patient has previously been treated with TNF inhibitors (as mentioned in the case), certolizumab may still be considered as a treatment option if he had experienced a positive but inadequate response to a different TNF inhibitor or if there were specific reasons to try a different medication within the same class.

Methotrexate is commonly used to treat rheumatoid arthritis and certain other autoimmune conditions. However, it is not considered a first-line treatment for axial spondyloarthritis.

# Managing Patients with Rheumatic Disorders in Primary Care



## References:

1. Deodhar A, van der Heijde D, Gensler LS, et al. Ixekizumab for patients with non-radiographic axial spondyloarthritis (COAST-X): a randomised, placebo-controlled trial. *Lancet*. 2020;395(10217):53-64. doi:10.1016/S0140-6736(19)32971-X
2. van der Horst-Bruinsma IE, de Vlam K, Walsh JA, et al. Baseline characteristics and treatment response to ixekizumab categorised by sex in radiographic and non-radiographic axial spondylarthritis through 52 weeks: Data from three Phase III randomised controlled trials. *Adv Ther*. 2022;39(6):2806-2819. doi:10.1007/s12325-022-02132-2
3. Deodhar A, Blanco R, Dokoupilová E, et al. Improvement of signs and symptoms of nonradiographic axial spondyloarthritis in patients treated with secukinumab: Primary results of a randomized, placebo-controlled phase III study. *Arthritis Rheumatol*. 2021;73(1):110-120. doi:10.1002/art.41477
4. Braun J, Blanco R, Marzo-Ortega H, et al. Two-year imaging outcomes from a phase 3 randomized trial of secukinumab in patients with non-radiographic axial spondyloarthritis. *Arthritis Res Ther*. 2023;25(1):80. Published 2023 May 16. doi:10.1186/s13075-023-03051-5
5. Sivera F, Núñez-Monje V, Campos-Fernández C, et al. Real-world experience with secukinumab in the entire axial spondyloarthritis spectrum. *Front Med (Lausanne)*. 2023;10:1156557. Published 2023 May 11. doi:10.3389/fmed.2023.1156557
6. Deodhar A, Van den Bosch F, Poddubnyy D, et al. Upadacitinib for the treatment of active non-radiographic axial spondyloarthritis (SELECT-AXIS 2): a randomised, double-blind, placebo-controlled, phase 3 trial. *Lancet*. 2022;400(10349):369-379. doi:10.1016/S0140-6736(22)01212-0
7. Deodhar A, Van den Bosch F, Poddubnyy D, et al. Upadacitinib for the treatment of active non-radiographic axial spondyloarthritis (SELECT-AXIS 2): a randomised, double-blind, placebo-controlled, phase 3 trial. *Lancet*. 2022;400(10349):369-379. doi:10.1016/S0140-6736(22)01212-0
8. Deodhar A, Gensler LS, Kay J, et al. A fifty-two-week, randomized, placebo-controlled trial of certolizumab pegol in nonradiographic axial spondyloarthritis. *Arthritis Rheumatol*. 2019;71(7):1101-1111. doi:10.1002/art.40866
9. van der Heijde D, Gensler LS, Maksymowych WP, et al. Long-term safety and clinical outcomes of certolizumab pegol treatment in patients with active non-radiographic axial spondyloarthritis: 3-year results from the phase 3 C-axSpAnd study. *RMD Open*. 2022;8(1):e002138. doi:10.1136/rmdopen-2021-002138

## ✦ Targeted treatments for SLE

A 24-year-old female visits the clinic reporting an 8-month history of fatigue, joint pain, and skin rash. She has flat, reddish, symmetrical plaques on her cheeks that worsen with sun exposure. She also experiences blistering rashes on sun-exposed areas, requiring intermittent systemic corticosteroids for resolution. Physical examination reveals tenderness and swelling in multiple small finger joints, oval-shaped scaly plaques on her cheeks with patchy hair loss on her scalp, and oral mucosal ulcerations on her hard palate. Laboratory tests show positive antinuclear antibodies and anti-double-stranded DNA antibodies. The patient is diagnosed with systemic lupus erythematosus without evidence of renal involvement. There has been minimal improvement after 2 months of treatment with hydroxychloroquine (5 mg/kg/day) and topical corticosteroids.

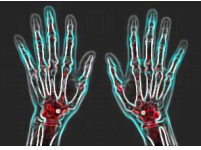
Which of the following targeted treatments would be an appropriate option for managing this patient with systemic lupus erythematosus (can select more than 1)?

- A. Anifrolumab
- B. Belimumab
- C. Continue hydroxychloroquine
- D. Cyclophosphamide
- E. Infliximab

**The correct answers are A, B, and C.**

Belimumab is a monoclonal antibody that specifically targets and inhibits B-lymphocyte stimulator (BLyS), a protein involved in the activation and survival of B cells, which play a role in the immune response and autoimmune diseases like systemic lupus erythematosus (SLE). Belimumab is FDA-approved for treating active SLE in adults without adequate response with standard therapies.<sup>1,2,3,4</sup> A post hoc pooled analysis of several clinical trials demonstrated that belimumab exhibited a consistent safety profile compared to

# Managing Patients with Rheumatic Disorders in Primary Care



placebo in adults with SLE, supporting its favorable benefit-risk profile for SLE treatment.<sup>5</sup> Given the patient's minimal improvement on hydroxychloroquine, adding belimumab to her treatment regimen could be a suitable option to target her immune dysregulation and manage her SLE symptoms. However, it is not a rapidly-acting medication.

While the patient has shown minimal improvement on hydroxychloroquine after 2 months, it is essential to consider that some SLE patients may take longer to respond to treatment. Hydroxychloroquine is a commonly used medication for SLE and is regarded as a first-line treatment.<sup>6</sup> It can be beneficial in controlling various SLE manifestations, including skin and joint symptoms. The decision to continue hydroxychloroquine should be based on the patient's overall response, the severity of her symptoms, and the assessment of potential risks and benefits. Another significant reason for the continuation of hydroxychloroquine is that it has been demonstrated to reduce the risk of systemic lupus flares.

Anifrolumab is a type I interferon receptor antagonist that inhibits the type I interferon pathway, which is believed to be dysregulated in SLE. It is FDA-approved for treating moderate to severe active SLE in adults who have not responded well to standard therapy.<sup>7,8,9</sup> A post hoc analysis of anifrolumab phase 3 trial data in patients with SLE

showed that anifrolumab treatment increased attainment of lupus low disease activity state compared to placebo, highlighting its potential to improve outcomes in SLE.<sup>10</sup> The TULIP Long-Term Extension study, investigating the effects of anifrolumab 300 mg in SLE patients who had previously participated in a trial, revealed a favorable safety profile, no new safety issues, and improvements in disease activity and reduction in glucocorticoid usage in comparison to the placebo group.<sup>11</sup> Given the patient's continued symptoms despite hydroxychloroquine treatment, anifrolumab could be a targeted treatment to address the underlying immune dysregulation in her SLE. The provision of a zoster vaccine should be considered before initiating therapy with anifrolumab.

Cyclophosphamide is an effective therapy for organ and life-threatening lupus activity. However, it has a problematic side effect profile, including the delayed risk of malignancies, cytopenias, infections, and ovarian failure.

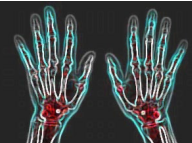
Infliximab is a tumor necrosis factor-alpha (TNF-alpha) inhibitor commonly used to treat autoimmune conditions such as rheumatoid arthritis and inflammatory bowel diseases. However, it is not considered a first-line treatment for SLE. TNF inhibitors in SLE have limited supporting evidence, and their role in managing the disease is less established than other targeted treatments such as belimumab or anifrolumab.

## References:

1. Wallace DJ, Stohl W, Furie RA, et al. A phase II, randomized, double-blind, placebo-controlled, dose-ranging study of belimumab in patients with active systemic lupus erythematosus. *Arthritis Rheum.* 2009;61(9):1168-1178. doi:10.1002/art.24699
2. Furie R, Petri M, Zamani O, et al. A phase III, randomized, placebo-controlled study of belimumab, a monoclonal antibody that inhibits B lymphocyte stimulator, in patients with systemic lupus erythematosus. *Arthritis Rheum.* 2011;63(12):3918-3930. doi:10.1002/art.30613
3. Navarra SV, Guzmán RM, Gallacher AE, et al. Efficacy and safety of belimumab in patients with active systemic lupus erythematosus: a randomised, placebo-controlled, phase 3 trial. *Lancet.* 2011;377(9767):721-731. doi:10.1016/S0140-6736(10)61354-2
4. Brunner HI, Abud-Mendoza C, Mori M, et al. Efficacy and safety of belimumab in pediatric and adult patients with systemic lupus erythematosus: an across-study comparison. *RMD Open.* 2021;7(3):e001747. doi:10.1136/rmdopen-2021-001747
5. Wallace DJ, Atsumi T, Daniels M, et al. Safety of belimumab in adult patients with systemic lupus erythematosus: Results of a large integrated analysis of controlled clinical trial data. *Lupus.* 2022;31(13):1649-1659. doi:10.1177/09612033221131183
6. PLAQUENIL® (hydroxychloroquine sulfate) tablets. Prescribing information. Sanofi-Aventis U.S. LLC. Accessed July 26, 2023. [https://www.accessdata.fda.gov/drugsatfda\\_docs/label/2007/009768s041lbl.pdf](https://www.accessdata.fda.gov/drugsatfda_docs/label/2007/009768s041lbl.pdf)



# Managing Patients with Rheumatic Disorders in Primary Care



7. Casey KA, Guo X, Smith MA, et al. Type I interferon receptor blockade with anifrolumab corrects innate and adaptive immune perturbations of SLE [published correction appears in *Lupus Sci Med*. 2018 Dec 22;5(1):e000286corr1]. *Lupus Sci Med*. 2018;5(1):e000286. Published 2018 Nov 22. doi:10.1136/lupus-2018-000286
8. Furie R, Morand EF, Askanase AD, et al. Anifrolumab reduces flare rates in patients with moderate to severe systemic lupus erythematosus. *Lupus*. 2021;30(8):1254-1263. doi:10.1177/09612033211014267
9. Morand EF, Furie R, Tanaka Y, et al. Trial of anifrolumab in active systemic lupus erythematosus. *N Engl J Med*. 2020;382(3):211-221. doi:10.1056/NEJMoa1912196
10. Morand EF, Abreu G, Furie RA, Golder V, Tummala R. Lupus low disease activity state attainment in the phase 3 TULIP trials of anifrolumab in active systemic lupus erythematosus. *Ann Rheum Dis*. 2023;82(5):639-645. doi:10.1136/ard-2022-222748
11. Kalunian KC, Furie R, Morand EF, et al. A randomized, placebo-controlled phase III extension trial of the long-term safety and tolerability of anifrolumab in active systemic lupus erythematosus. *Arthritis Rheumatol*. 2023;75(2):253-265. doi:10.1002/art.42392

## ◆ Gout Management

A 48-year-old man presents for his annual physical examination. He has a history of treated hypertension and treated tophaceous gout (left ear and right olecranon bursa) for several years. He had a non-ST elevated MI 2 years ago, his recent stress test showed no inducible ischemia, and he exercises regularly without limitation. His last attack of gout was “mild” and occurred in the left foot over 6 months ago. It promptly resolved after several doses of over-the-counter naproxen.

His current medications include losartan (50 mg/d), colchicine (0.6 mg/d), allopurinol (400 mg/d), HCTZ (25 mg/d), atorvastatin (80 mg/d), and ASA (81 mg/d). His blood pressure is 136/82 mmHg. He has several nontender pea-sized movable right olecranon nodules, a single nontender left ear helix nodule, no joint tenderness, and bilateral “bunions.” The remainder of the examination is normal. All laboratory studies are in the normal range, including his urate level of 6.8 mg/dL and creatinine of 0.6 mg/dL.

Which of the following are the most appropriate next steps in his management?

- A. Continue colchicine and change allopurinol to febuxostat 80 mg; discontinue hydrochlorothiazide (use naproxen for flares if necessary).
- B. Continue colchicine and increase allopurinol dose to 500 mg/d; continue hydrochlorothiazide (take naproxen if needed for flares)
- C. Discontinue colchicine and change allopurinol to febuxostat 80 mg; continue

hydrochlorothiazide (use naproxen for flares if necessary).

- D. Discontinue colchicine and increase allopurinol dose to 500 mg; discontinue hydrochlorothiazide (use naproxen for flares if necessary).

## The correct answer is B.

Although the urate level is in the laboratory’s “normal range,” it remains above the ex-vivo urate saturation point of 6.8 mg/dL – hence additional urate-lowering therapy is warranted in a man who still is experiencing gout flares and has palpable tophi. The suggested target for urate-lowering therapy by several specialty societies is <6.0 mg/dL. Keeping the serum urate below its estimated saturation point has resulted in the dissolution of uric acid deposits and, ultimately, the resolution of gout flares. Since the speed at which the dissolution of deposits occurs is inversely associated with serum urate levels, some societies and many clinicians suggest even a lower serum urate target for at least as long as the tophi persist. A serum urate level of <6 mg/dL should be maintained for life; if the level increases, deposition will reoccur, and flares will likely begin again. Because he still has tophi, and additional urate lowering is warranted, he should stay on the colchicine to prevent or limit the number of “mobilization flares” that may occur as the urate is dissolved. Colchicine can be stopped once it is assumed that the deposits have resolved. An additional possible benefit of colchicine, shown in several studies, is that it may reduce the occurrence of cardiac events. Since gout flares have been associated temporally with cardiac events, prevention of flares may be of benefit for reasons other than simply avoiding the painful flares.

# Managing Patients with Rheumatic Disorders in Primary Care



Allopurinol, which he tolerates, can be increased to achieve the target serum urate level. The FDA suggested limit is 800 mg daily (higher doses had not been well evaluated at the time of drug approval). At doses above 300 mg, splitting the dose may improve the bioavailability; 300 mg AM and 200 mg PM would be reasonable in this patient. Confirming that the patient had been regularly taking the 400 mg dose daily would also be important. Discussing dietary restrictions such as avoiding fructose corn syrup, excessive beer (including nonalcoholic beer) and alcohol, organ meats, and other ultra-high purine animal substances would also be reasonable. However, diet alone is not likely to lower the serum urate sufficiently.

Switching the allopurinol to febuxostat 80 mg is a reasonable option to lower the serum urate, as some patients may be resistant to allopurinol. However, The FDA maintains a “black box warning” on febuxostat over concerns from the CARES trial of increasing the risk of cardiac-related death. Subsequent studies have not confirmed this observation, and the CARES trial has been criticized for several methodologic issues. Nonetheless, some physicians continue to have concerns. Given that the patient’s blood pressure is not optimized, it would not be prudent to discontinue the HCTZ; stopping the HCTZ would likely only reduce the serum urate by about 0.8 mg/dL\*.

## References:

1. McAdams DeMarco MA, Maynard JW, Baer AN, et al. Diuretic use, increased serum urate levels, and risk of incident gout in a population-based study of adults with hypertension: the Atherosclerosis Risk in Communities cohort study. *Arthritis Rheum.* 2012;64(1):121-129. doi:10.1002/art.33315
2. Mackenzie IS, Ford I, Nuki G, et al. Long-term cardiovascular safety of febuxostat compared with allopurinol in patients with gout (FAST): a multicentre, prospective, randomised, open-label, non-inferiority trial. *Lancet.* 2020;396(10264):1745-1757. doi:10.1016/S0140-6736(20)32234-0
3. O'Dell JR, Brophy MT, Pillinger MH, et al. Comparative effectiveness of allopurinol and febuxostat in gout management. *NEJM Evid.* 2022;1(3):10.1056/evidoa2100028. doi:10.1056/evidoa2100028